



ELSO Interim Guidelines for Venoarterial Extracorporeal Membrane Oxygenation in Adult Cardiac Patients

ROBERTO LORUSSO^{ID,*} KIRAN SHEKAR,[†] GRAEME MACLAREN^{ID,‡} MATTHIEU SCHMIDT,[§] VINCENT PELLEGRINO,[¶] BART MEYNS^{||} JONATHAN HAFT,[#] LEEN VERCAEMST,^{||} FEDERICO PAPPALARDO,^{**} CHRISTIAN BERMUDEZ,^{††} JAN BELOHLAVEK^{ID,‡‡} XIAOTONG HOU,^{§§} UDO BOEKEN,^{¶¶} ROBERTO CASTILLO,^{|||} DIRK W. DONKER^{ID,###} DARRYL ABRAMS,^{†††} MARCO RANUCCI,^{‡‡‡} KASIA HRYNIEWICZ,^{§§§} IVAN CHAVEZ,^{§§§} YIH-SHARNG CHEN,^{¶¶¶} LEONARDO SALAZAR,^{|||} AND GLENN WHITMAN^{###}

REVIEWERS: Hergen Buscher,^{****} Rodrigo Diaz,^{††††} Thomas Mueller,^{‡‡‡‡} AND Alain Combes,^{§§§§}

Over the past decade, the use of extracorporeal membrane oxygenation (ECMO) has increased exponentially, from approximately 30–40 patients per year in the United States 20 years ago, to over 2,000 per year currently, and rising.¹ The increased

utilization of ECMO has resulted from improved cannulation techniques, including percutaneous approach, as well as advances in the technology of the pumps, oxygenators, and cannulas. Despite these features, however, choosing appropriate candidates and managing their daily care can be extremely challenging. What follows is an in-depth discussion of the indications for venoarterial (VA) ECMO in adult patients affected by cardiac disease, the manner of its application, the physiology underlying the care for these patients, and the assessment and treatment of complications, including ethical and organizational issues.

More in-depth material and information are provided in the Extracorporeal Life Support Organization (ELSO) 5th Edition Red Book.² Furthermore, the recent ELSO indications about ECLS and cannulation nomenclature will be followed in this guideline.^{3,4}

Decision Making in Adult VA ECMO for Acute Cardiac Failure

VA ECMO may support patients for days or weeks as a “bridge-to-decision” that includes weaning after recovery of cardiac function, transplantation, long-term mechanical circulatory support (MCS), and withdrawal in the case of futility. Dedicated documents for the use of VA ECMO in the setting of cardiac arrest and postcardiotomy in adult patients are addressed by additional ELSO guidelines and as joint society position paper (expert consensus of EACTS/ELSO/STS/AATS).⁵

Indications

Specific physiologic goals, monitoring, and patient selection. Cardiogenic shock suitable for ECMO is generally characterized by systemic systolic pressure less than 90, urine output <30 ml/hour, lactate over 2, SVO₂ less than 60%, altered conscious state for 6 hours unresponsive to optimal treatment (Table 1). The goal is to maintain systemic oxygen delivery at least 3 times oxygen consumption (the DO₂:VO₂ ratio is >3) (normal is 5, shock is 2): O₂ delivery is arterial oxygen content (normal 20 ml/dl) times cardiac output (normal 30 dl/m²/min). In VA ECMO access, addressing the goal is easy because the cardiac output is the ECMO flow and the arterial hemoglobin saturation is 100%, so content is easily calculated, knowing the hemoglobin concentration (normal 15 g/dl). In VA ECMO, the drainage blood saturation (the SVO₂) measures the DO₂:VO₂ ratio, and SVO₂ is measured continuously. If the arterial saturation is 100% and the venous sat is 80%, the ratio is 5:1. So,

*Cardio-Thoracic Surgery Department, Maastricht University Medical Centre (MUMC), Cardiovascular Research Institute Maastricht (CARIM), Maastricht, The Netherlands; †Adult Intensive Care Unit, The Prince Charles Hospital, Brisbane, Queensland, Australia; ‡Cardio-Thoracic Intensive Care Unit, National University Hospital, Singapore, Singapore; §Medical Intensive Care Unit, Hopital La Pitie-Salpêtrière, University Pierre et Marie Curie, Paris, France; ¶Intensive Care Unit, The Alfred Hospital, Monash University, Melbourne, Victoria, Australia; ||Cardiac Surgery Unit, Gasthuisberg University Hospital, Catholic University, Leuven, Belgium; #Section of Cardiac Surgery, University of Michigan, Ann Arbor, Michigan; **Department of Anesthesia and Intensive Care, IRCCS ISMETT, UPMC, Palermo, Italy; ††Department of Cardiovascular Surgery, Hospital of the University of Pennsylvania, Philadelphia, Pennsylvania; ‡‡2nd Department of Medicine, Cardiovascular Medicine, General University Hospital, Charles University, Prague, Czech Republic; §§Cardiac Intensive Care, Beijing Anzhen Hospital, Capital Medical University, Beijing, China; ¶¶Department of Cardiac Surgery, Heinrich-Heine-University, Düsseldorf, Germany; |||Unidad ECMO, Clínica Las Condes, Santiago, Chile; ###Intensive Care Unit, Utrecht University Medical Centre, Utrecht, The Netherlands; ****CRPH Cardiovascular & Respiratory Physiology Group, TechMed Centre, Faculty of Science & Technology, University of Twente, Enschede, The Netherlands; ††† Division of Pulmonology, Allergy and Critical Care, NewYork Presbyterian Hospital, Columbia University, New York, New York; ‡‡‡Cardio-Thoracic and Vascular Anesthesia and ICU Department, IRCCS Policlinico San Donato Hospital, Milan, Italy; §§§Minneapolis Heart Institute Foundation, Abbot Northwestern University, Minneapolis, Minnesota; ¶¶¶Cardiovascular Centre, National Taiwan University Hospital, Taiwan, Taipei; |||||Department of Intensive Care, Fundación Cardiovascular de Colombia, Bucaramanga, Colombia; ###Cardiovascular Surgery Intensive Care Unit and Heart Transplant, Johns Hopkins Hospital, Baltimore, Maryland; ****University of Sydney, Australia; ††††Santiago del Chile, Chile; ‡‡‡‡University of Regensburg, Germany; and §§§§University of Paris, France.

Submitted for consideration March 2021; accepted for publication in revised form March 2021.

Dr. Lorusso is the consultant for LivaNova, Getinge, and Medtronic, and member of the Advisory Board of Eurosets (all honoraria for presentation paid to the University for research funding). The remaining authors have no conflicts of interest to report.

Correspondence: Roberto Lorusso, MD, PhD, FELLO, FEACTS, Cardiac Surgery and Extracorporeal Life Support, Department of Cardio-Thoracic Surgery, Heart & Vascular Centre, Maastricht University Medical Centre (MUMC), Cardiovascular Research Institute Maastricht (CARIM), P. Debyelaan 25, Maastricht 6202 AZ, The Netherlands. E-mail: roberto.lorusso@gmail.com.

Copyright © ELSO 2021

DOI: 10.1097/MAT.0000000000001510

Table 1. Clinical Features of Cardiogenic Shock and Defined Contemporary Trials and Guidelines

Clinical Trial/ Guidelines	Cardiogenic Shock Criteria
SHOCK Trial (1999)	<ul style="list-style-type: none"> • SBP < 90 mm Hg or vasopressor support to maintain SBP > 90 mm Hg • Evidence of end-organ damage (UO < 30 ml/h or cool extremities)
IABP-SOAP II (2012)	<ul style="list-style-type: none"> • Hemodynamic criteria: CI < 2.2 and PCWP > 15 mm Hg • MAP < 70 mm Hg or SBP < 100 mm Hg despite adequate fluid resuscitation (at least 1 L of crystalloid or 500 ml of colloids)
EHS-PCI (2012)	<ul style="list-style-type: none"> • Evidence of end-organ damage (AMS, mottled skin, UO < 0.5 ml/kg/h for 1 h or serum lactate > 2 mmol/L) • SBP < 90 mm Hg for 30 min or inotropes use to maintain SBP > 90 mm Hg
ESC-HF Guidelines (2016)	<ul style="list-style-type: none"> • Evidence of end-organ damage and increased filling pressure • SBP < 90 mm Hg with appropriate fluid resuscitation with clinical and laboratory evidence of end-organ damage
KAMIR-NIH (2018)	<ul style="list-style-type: none"> • Clinical: cold extremities, oliguria, AMS, narrow pulse pressure. Laboratory: metabolic acidosis, elevated serum lactate, elevated serum creatinine • SBP < 90 mm Hg for > 30 min or supportive intervention to maintain SBP > 90 mm Hg • Evidence of end-organ damage (AMS, UO < 30 ml/h, or cool extremities)

AMS, altered mental status; CI, cardiac index; EHS-PCI, Euro-Heart Survey Percutaneous Coronary Intervention Registry; ESC-HF, European Society of Cardiology—Heart Failure; IABP-SOAP II, Intra-aortic balloon pump in cardiogenic shock II; KAMIR-NIH, Korean Acute Myocardial Infarction Registry—National Institute of Health; MAP, mean arterial pressure; PCWP, pulmonary capillary wedge pressure; SBP, systolic blood pressure; SHOCK, Should We Emergently Revascularize Occluded Coronaries for Cardiogenic Shock; UO, Urine output.

adjusting flow and hemoglobin to maintain SVO_2 over 66% assures that the goal of $DO_2/VO_2 > 3$ is met. Additional details are described in the Red Book chapter on physiology.²

Short-term MCS should be considered in patients with refractory cardiogenic shock with a potentially reversible or surgically correctable cause.⁶ Compared with other percutaneous temporary MCS, VA ECMO has advantages for patients with severe biventricular failure or in case of malignant arrhythmia as well as associated pulmonary failure. The classical scenario where VA ECMO should be considered occurs when medical treatment, including fluids, inotropes, and, potentially, intra-aortic balloon pump (IABP), fails. Ideally, VA ECMO should be initiated before multiorgan failure and after thorough echocardiography evaluation. The patient's age, comorbidities, and prognosis of the underlying illness should also be factored into the ECMO decision making. Age *per se*, however, should not be considered an absolute contraindication, especially when greater prospects of cardiac recovery exist, given that the suitability for bridging durable MCS and heart transplantation may diminish with advancing age.

Common situations for ECMO are patients with medical (acute myocardial infarction, fulminant myocarditis, intoxication with cardiotoxic drugs, end-stage dilated or ischemic cardiomyopathy, hypothermia with refractory cardiocirculatory instability, and massive pulmonary embolism), and postsurgical (including posttransplantation) acute cardiogenic shock. Other emerging indications for VA ECMO are shown in Figure 1.

- Cardiac recovery unlikely and no indication for heart transplant or durable left ventricular (LV) assist device
- Poor life expectancy (end-stage peripheral-organ diseases, malignant tumor, massive pulmonary embolisms in cancer patients, chemotherapy-induced chronic cardiomyopathy, etc.)
- Severe aortic valve regurgitation
- Severe vascular disease with extensive aortic and peripheral vessel involvement (calcification, stenosis, and closure), including axillary arteries
- Acute Type A or B aortic dissection with extensive aortic branches (ascending, supra-aortic and femoral) involvement (preoperatively)
- Severe neurologic impairment (*i.e.*, prolonged anoxic brain damage, extensive trauma and bleeding)
- Severe immunologic disease with marked blood and coagulation disorders
- Liver cirrhosis (Child-Pugh class B and C)

Contraindications

Regarding the contraindications for VA ECMO implant, these are listed below:

Pre-ECMO Risk Prediction (Risk Scores)

In the last few years, several risk scores have been proposed to assess the VA ECMO patient outcomes, to stratify patients' risk of mortality, and to improve the patient selection.

The survival after VA ECMO score (Table 2) is a survival prediction score based on the large pre-ECMO assessment data extracted from the ELSO registry.⁷ The survival after VA ECMO score is the first reported in-hospital survival prediction model for ECLS use in cardiogenic shock but does not apply to post-cardiotomy settings. Other scores have been designed regarding ECMO in cardiogenic shock, including general or specific VA ECMO settings and described in Table 3.^{8–10}

Recommendations

- VA ECMO should be considered for cardiogenic shock within 6 hours of its occurrence, refractory to conventional pharmacological and fluid therapy, and in patients with reversible cardiocirculatory collapse or those eligible for alternative cardiocirculatory assistance, for example, ventricular assist devices (VADs) or transplantation.
- Etiologies compromising appropriate ECMO function (aortic insufficiency) should be considered to represent potential contraindications.
- Age, *per se*, should not be used as an absolute contraindication.
- Prognostic score may be used to provide information regarding decision making before ECMO.
- Poor life expectancy, severe liver disease, acute brain injury, vascular disease, and immunocompromise represent exclusion criteria for ECMO application.

Cannulation, Distal Perfusion, and Left Ventricular Venting

All aspects and information regarding ECMO circuits, systems, and modes are also presented in other ELSO position papers and in the ELSO Red Book.^{2–4}

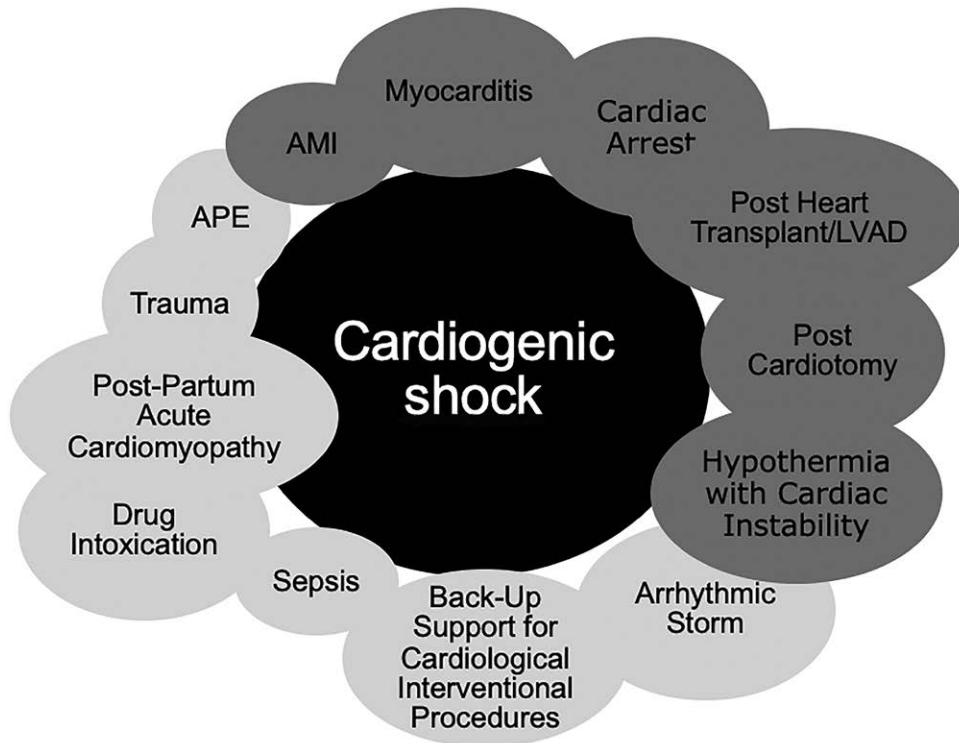


Figure 1. Common (dark gray) and emerging situations (light gray) for venoarterial extracorporeal life support in the context of cardiogenic shock. AMI, acute myocardial infarction; APE, massive pulmonary embolism; LVAD, left ventricular assist device; Sepsis, sepsis-associated cardiomyopathy.

Peripheral Cannulation

Peripheral VA ECMO cannulation is the most frequently applied for access and performed *via* the common femoral artery and vein just below the inguinal ligament and above their respective bifurcations (Figure 2). A 15–17 French arterial cannula is usually adequate to supply sufficient flow depending on the patient’s needs. Larger 19 or 21 French cannulas may be necessary in rare clinical scenarios such as sepsis when higher flow is desired.¹¹ Larger arterial cannulas might be associated with increased vascular complications, including limb ischemia.

Although the result of expert-opinion only, it is felt preferable to place the arterial and venous cannulas in separate limbs to reduce vascular complications and to facilitate decannulation. If feasible, the venous cannula should be placed in the right femoral vein as it is a more direct path to the IVC and right atrium (Figure 3).¹²

Image-guided cannulation, particularly vascular ultrasound as a first choice, is recommended. Fluoroscopy can be useful in certain circumstances, for example, implantation in the cath lab. Vascular ultrasound should be started in the short axis and longitudinal views. We recommend starting in the short-axis view, identifying the common femoral artery and vein, the superficial and profunda femoral arteries (Figure 4A), then rotating 90° to the longitudinal view. This affords visualization of the common femoral artery and bifurcation (Figure 4B). It optimizes anterior entry of the needle into the vessel and avoids posterior wall puncture. In addition, using the femoral head as a landmark can ensure vascular access is at a compressible portion of the vessel and avoids pelvic entry (Figure 4C). Similar techniques are recommended for entering the common femoral vein.

After administration of adequate anticoagulation, a standard guidewire is advanced in the respective vessels and a series of progressive dilations are performed to facilitate cannula insertion. In certain situations, such as obesity, tortuous anatomy, and peripheral vascular disease, a stiff guidewire may be needed for support. The cannulas are then advanced into their respective femoral artery and vein. Imaging (ultrasound, fluoroscopy, or x-ray film) is recommended to confirm initial wire position, directing the advancement of the guidewire, and confirming placement of the arterial and venous drainage cannulas (Figures 5 and 6). Standard chest x-ray film is sufficient to confirm appropriate cannula position after implant.

Subclavian or axillary artery cannulation can be used as a form of peripheral access.² This access may be used in patients with peripheral vascular disease or very difficult femoral artery access so as to prevent vascular cannulation complications occurring at the femoral artery site, including leg ischemia, bleeding, vascular perforation or rupture, and inadequate cannula size. Furthermore, this access site can (a) minimize differential oxygenation, (b) facilitate patient mobilization in the case of a predicted long VA ECMO run, and (c) allow transition to isolated LV support. In this case, a pseudo-percutaneous approach or the use of a tube graft connection to the axillary artery may be helpful with incision closure while minimizing infection complication. As opposed to ischemia, upper limb hyperperfusion with arm swelling is the more common vascular complication as a result of high ECLS flow with no limitation to ipsilateral limb perfusion, as can occur in the case of a “chimney technique” with a prosthetic graft, as discussed later in this section. The cannulation of the subclavian artery may be carried out similarly, directly or with a “chimney graft”

Table 2. The SAVE Score⁶

Parameter	Score	
Acute cardiogenic shock diagnosis group (select one or more)		
Myocarditis	3	
Refractory VT/VF	2	
Post heart or lung transplantation	3	
Congenital heart disease	-3	
Other diagnoses leading to cardiogenic shock requiring VA ECMO	0	
Age (yrs)		
18-38	7	
39-52	4	
53-62	3	
≥63	0	
Weight (kg)		
≤65	1	
65-89	2	
≥90	0	
Acute pre-ECMO organ failures (select one or more if required)		
Liver failure*	-3	
Central nervous system dysfunction†	-3	
Renal failure‡	-3	
Chronic renal failure§	-6	
Duration of intubation before initiation of ECMO (h)		
≤10	0	
11-29	-2	
≥30	-4	
Peak inspiratory pressure ≤20 cmH ₂ O	3	
Pre-ECMO cardiac arrest	-2	
Diastolic blood pressure before ECMO ≥ 40 mmHg¶	3	
Pulse pressure before ECMO ≤20 mmHg¶	-2	
HCO ₃ before ECMO ≤15 mmol/L¶	-3	
Constant value to add to all calculations of SAVE score	-6	
Total score	-35 to 17	
Total SAVE score	Risk class	Survival (%)
>5	I	75
1-5	II	58
-4 to 0	III	42
-9 to -5	IV	30
≤ -10	V	18

An online calculator is available at www.save-score.com.

*Liver failure was defined as bilirubin ≥33 μmol/L or elevation of serum aminotransferases (ALT or AST) >70 U/L.

†CNS dysfunction combined neurotrauma, stroke, encephalopathy, cerebral embolism, as well as seizure and epileptic syndromes.

‡Renal dysfunction is defined as acute renal insufficiency (e.g., creatinine >1.5 mg/dl) with or without RRT.

§Chronic kidney disease is defined as either kidney damage or glomerular filtration rate <60 ml/min/1.73 m² for ≥3 mo.

¶Worse value within 6 h prior ECMO cannulation.

ALT, alanine transaminase; AST, aspartate aminotransferase; ECMO, extracorporeal membrane oxygenation; CNS, central nervous system; RRT, renal replacement therapy; SAVE, Survival After Venoarterial Extracorporeal Membrane Oxygenation; VF, ventricular fibrillation; VT, ventricular tachycardia.

for access. Finally, although usually confined to the pediatric population, carotid artery cannulation can be used for arterial access, recognizing the increased risk of acute brain injury,¹³ thereby making it the access of last resort when femoral, axillary/subclavian, or a central approach are not feasible.

Distal Perfusion

With peripheral femoral cannulation, distal perfusion ipsilateral to the femoral artery cannulation is recommended.²

Distal perfusion catheters should be placed under ultrasound guidance or under direct vision into the superficial femoral artery. If the approach is percutaneous, access should start with a puncture in the common femoral artery below the arterial cannula but above the bifurcation and guided into the superficial femoral artery (Figure 4C). Confirmation of the guide wire in the superficial femoral artery by ultrasound or fluoroscopy may be considered, and confirmation of flow by continuous-flow Doppler and ultrasound of the popliteal artery is recommended. When using smaller 15 Fr and 17 Fr arterial cannulas, distal limb perfusion may not be always needed with decision making informed by Near-Infrared Spectroscopy (NIRS). Tissue saturation by NIRS should be above 50%, preferably 60%, and there should be less than a 20% difference between the two extremities. In principle, however, distal perfusion is recommended with a short 6 Fr-8 Fr armored cannula.² Larger and longer sheaths may be associated with vascular trauma and spasm. The sidearm of the distal perfusion sheath is connected with short tubing using a male-to-male connector to the vent port of the arterial cannula (Figure 3). Retrograde limb perfusion through the dorsalis pedis or the posterior tibial arteries might be also considered not requiring any fluoroscopy or echo guidance to perform it.² When possible, measurement of flow confirms adequate tissue perfusion, targeting at least 100 ml/min. Finally, it is recommended that distal limb perfusion be accomplished at the time of ECMO institution, preventing any delays in limb perfusion.

Left Ventricular Venting Strategies

A major disadvantage of VA ECMO is the potential for significant LV loading and distension due to the increase in aorta afterload and associated poor LV ejection. This may be especially harmful for the acutely infarcted left ventricle. High afterload and poor LV ejection may impair aortic valve opening leading to acute pulmonary edema or catastrophic thrombosis of the left-sided cardiac chambers or the aortic root. Thus, the threshold for LV venting in VA ECMO should be low and initially guided by the clinical/imaging scenario (Figure 7).¹⁴

Pulmonary edema on chest x-ray film, a pulse pressure less than 5-10 mmHg, LV "smoke-like" visualization, and a closed aortic valve with LV distension on echocardiogram all should trigger prompt intervention.¹⁴ Noninvasive techniques, including a reduction of ECMO flow while still sustaining effective end-organ perfusion, vasodilation to directly reduce peripheral arterial resistance, increased PEEP to reduce pulmonary arterial flow and enhance right cardiac drainage toward the ECMO system, or moderate inotropic support to maintain LV ejection, all represent possible noninvasive approaches to managing LV distension.¹⁴ In principle, impaired LV unloading compromises myocardial recovery and should be addressed immediately when present (Table 4).

Various strategies for more aggressive LV venting and unloading include the temporary percutaneous axial flow LV assist device (LVAD) (Impella; Abiomed, Danvers, MA), atrial septostomy or direct drainage, or direct LV apical cannulation and decompression. Intra-aortic balloon pump with inotropes may assist in unloading as well, but data to support this practice are still limited although widely practiced. The favorable impact of LV venting on weaning and early survival have been recently highlighted^{15,16} indicating that such an important

Table 3. Published Risk Scores for Venoarterial Extracorporeal Life Support, Besides the SAVE Score

Risk Score Name ^{Reference}	VA ECMO Setting	Predictors
ENCOURAGE Score ⁷	Cardiogenic shock (post AMI)	Age, sex, BMI, Glasgow Coma Scale, creatininemia, serum lactate value, prothrombin activity
REMEMBER Score ⁸	Post cardiotomy cardiogenic shock (post CABG)	Older age, left main coronary artery disease, Inotropic score, CK-MB, serum creatinine, platelet count
CARDShock Score ⁹	Cardiogenic shock	Older age, neurologic status, previous myocardial infarction or CABG, blood lactate value, acute coronary syndrome etiology, LV systolic dysfunction, estimated glomerular filtration

AMI, acute myocardial infarction; BMI, body mass index; CABG, coronary artery bypass grafting; CK-MB, creatinine kinase-myocardial band; LV, left ventricular; VA ECMO, venoarterial extracorporeal membrane oxygenation.

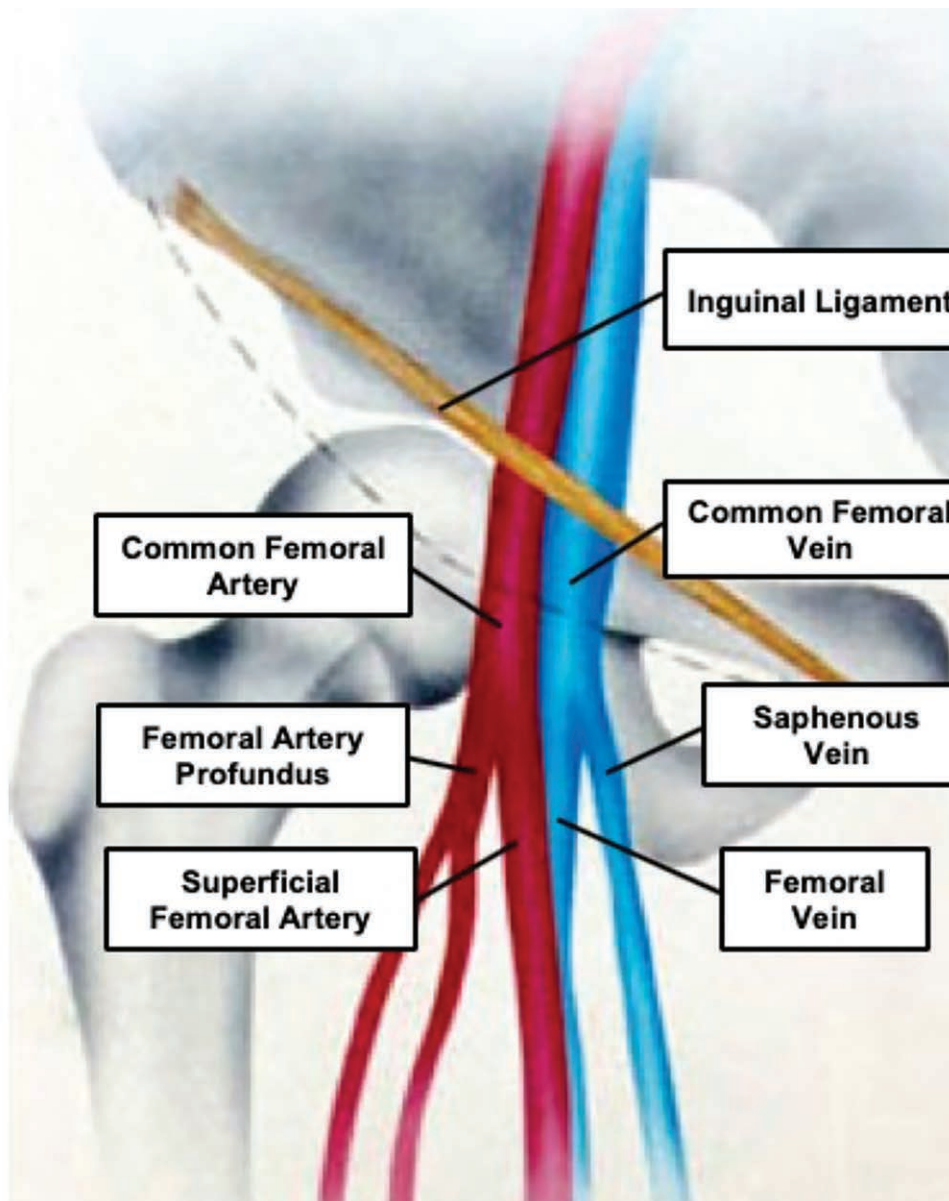


Figure 2. Right femoral vascular anatomy demonstrating relationship between the common femoral artery, vein, inguinal ligament, and femoral head.

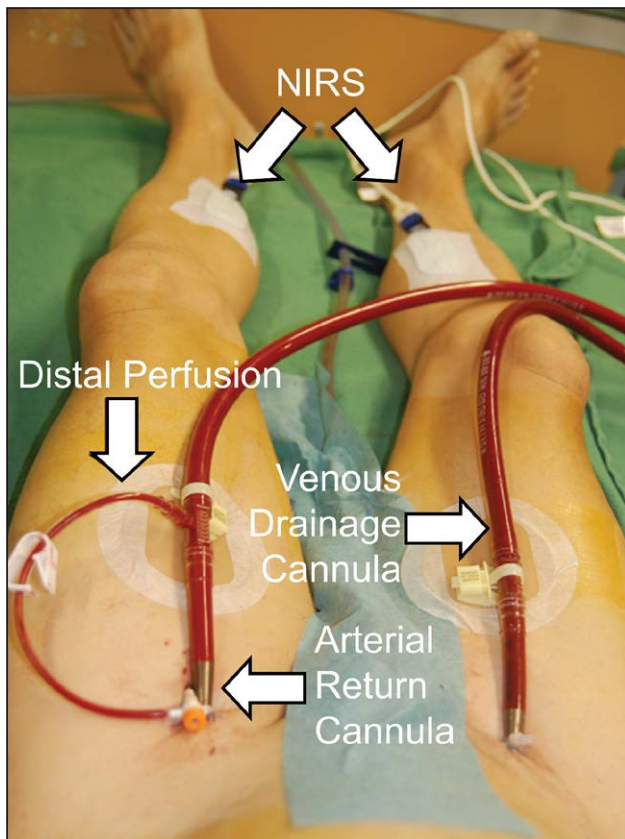


Figure 3. Bilateral peripheral VA ECLS cannulation demonstrating the relationship of the venous and arterial cannula, distal perfusion cannula and distal NIRS patches (modified from Rupprecht et al.).¹² NIRS, near-infrared spectroscopy; VA ECLS, venoarterial extracorporeal life support.

aspect of cardiac support with VA ECMO must receive adequate attention and monitoring to enhance appropriate and timely intervention.

Central Cannulation

Particularly in the presence of severe peripheral vascular disease at the femoral/iliac levels, central cannulation is usually adopted in the postcardiotomy setting, although recent investigations indicate that even in this setting, if possible, intraoperative transition to a peripheral approach provides better outcomes.² When central cannulation is decided upon postcardiotomy, use of the CPB-related cannulas (ascending aorta for perfusion and right atrium for drainage) is common. The adoption of prosthetic graft attached to the aorta is usually instituted after aortic surgery but can be adopted also as a solution to allow sternal closure.¹⁷ There are several advantages and disadvantages when comparing central to peripheral cannulation (Table 5); however, peripheral cannulation appears linked to better ultimate outcomes and should be considered preferable to a central approach, even in postcardiotomy patients.^{18,19}

Recommendations

- Peripheral cannulation may be associated with improved outcomes, and in cases of severe vascular disease, subclavian, or axillary artery cannulation should be considered.

- Ipsilateral limb perfusion is recommended at the time of initial femoral artery cannulation.
- Central cannulation may be considered in postcardiotomy and when faced with severe peripheral vascular disease.
- LV venting should be immediately addressed when LV distension is present as it is associated with increased weaning rates and early survival (data to be confirmed).
- LV venting can be noninvasive or invasive with MCS or with left-sided percutaneous or direct cannulation.

Configurations and Peculiarities

Factors considered when planning the initial cannulation strategy for MCS include:

- the underlying cause of cardiac dysfunction and projected time course of recovery;
- the severity of pulmonary dysfunction and projected time course of recovery;
- the functional reserve of each ventricle;
- the presence and severity of valvular pathology;
- risk of arterial access and size of vessels;
- the severity of coagulopathy and risk of sternotomy;
- planned future surgery, such as durable VAD implantation or transplant.

For patients with predominant cardiac failure and preserved pulmonary function, there are several options for MCS based on ECLS circuitry (Table 6).

Given its less invasive nature (compared with thoracic access), peripheral VA ECMO, with attention to avoid or minimize LV distension, is a viable first-line option for patients with isolated acute cardiac failure refractory to conventional management.

The limitations of peripheral VA ECMO have prompted the use of ECMO devices to facilitate LV unloading by changing to a temporary LVAD or a biVAD configuration (Figure 8).²⁰

Any perfusion strategy that creates a right to left shunt requires an oxygenator in the circuit. Oxygenators may additionally provide temperature control. This strategy effectively provides biventricular support and gas exchange through a single pump configuration with the ability to cease right ventricular (RV) support when not required. However, this configuration requires sternotomy and cannulation of the left ventricle (or left atrium) and aorta. Reoperation (sternotomy or thoracotomy) is then required for explantation of the cannula upon cardiac recovery or for implantation of a long-term mechanical assist device. Less invasive techniques for temporary cardiorespiratory support, including a transition strategy to an intermediate-term support configuration allowing mobilization, have been described (Figure 9). Although this configuration requires a left thoracotomy, sternotomy is avoided, potentially reducing the risk for subsequent surgery in the absence of cardiac recovery (long-term LVAD implantation as a bridge to destination or heart transplantation).

Temporary RV support can be provided with an ECMO system in case of the need of associated respiratory support (so called OxyRVAD) or without (therefore realizing an isolated RVAD configuration), through percutaneous femoral venous access to the right atrium and return to the pulmonary artery

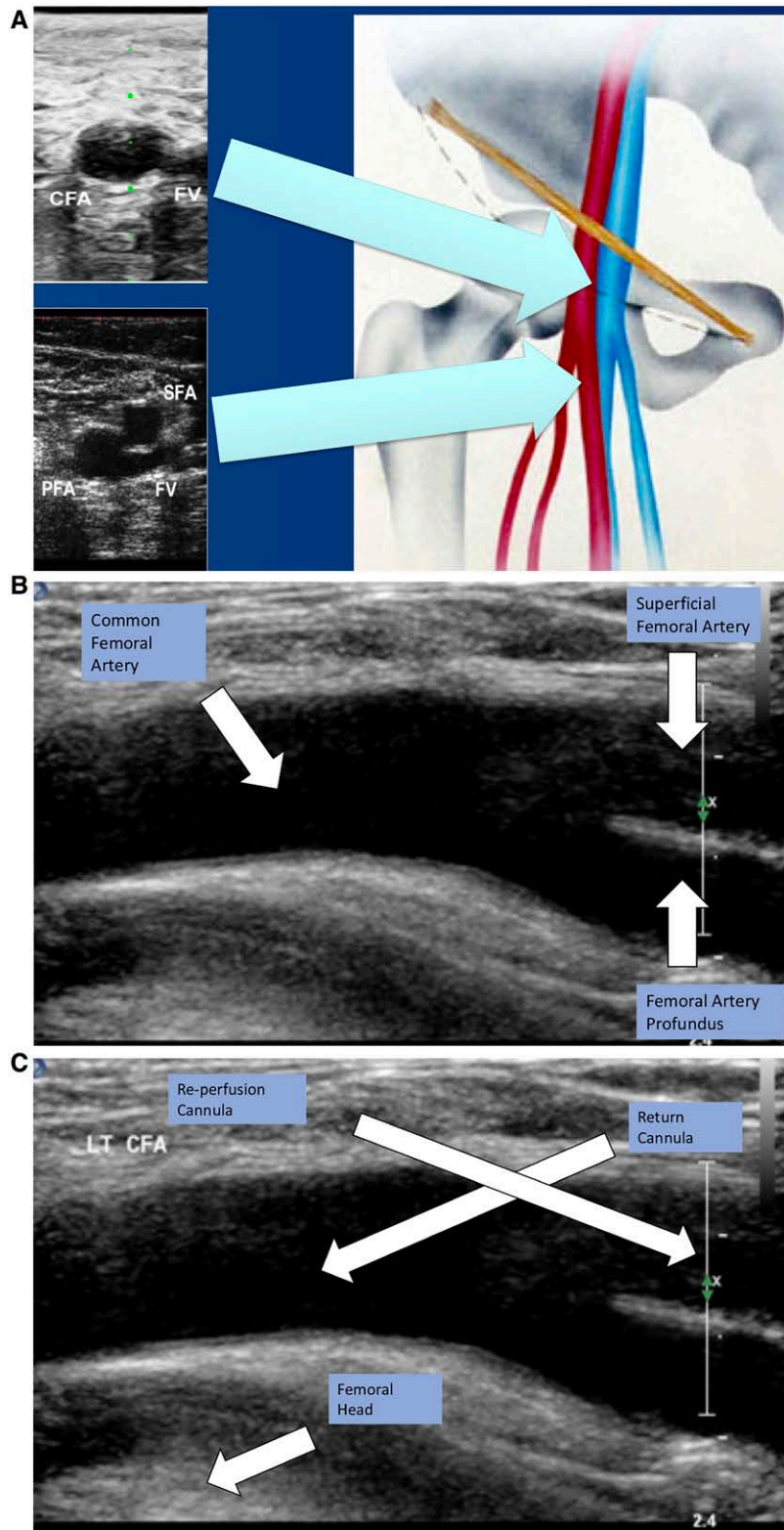


Figure 4. A: Vascular ultrasound in short axis of demonstrating the relationship of the CFA and CFV, the bifurcation of the SFA and PFA, inguinal ligament and femoral head. Note the FV courses below the superficial femoral artery. B: Longitudinal vascular ultrasound of the CFA as it bifurcates to the superficial femoral artery and the PFA. C: Longitudinal vascular ultrasound of the femoral artery demonstrating the relationship to the femoral head and the needle entry position of the arterial return cannula and the distal perfusion catheter (By courtesy of Dr. Wallace Ngai, Hong Kong). CFA, common femoral artery; CFV, common femoral vein; FV, femoral vein; PFA, profound femoral artery; SFA, superficial femoral artery.

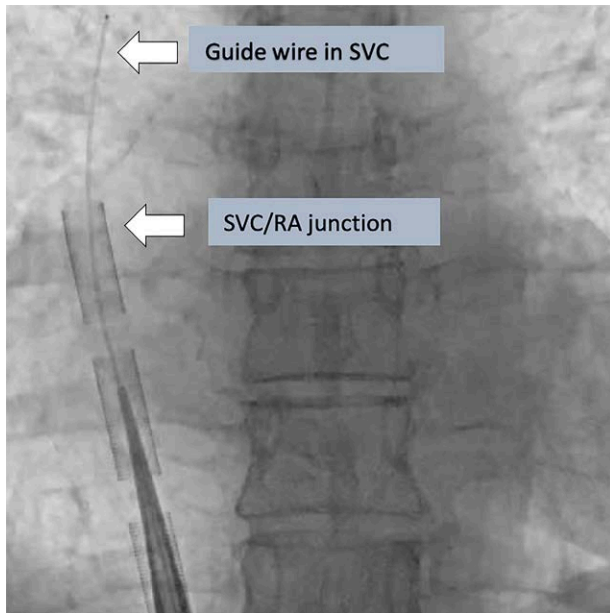


Figure 5. Fluoroscopy position of the guidewire in the SVC and the tip of the drainage cannula at the SVC/RA junction (By courtesy of Dr. Wallace Ngai, Hong Kong). SVC, superior vena cava; RA, right atrium.

via a cannulated exteriorized Dacron graft. This strategy is described for temporary support of the RV with insertion of a long-term LVAD but is applicable to other causes of severe isolated RV dysfunction.²¹ Upon RV recovery, the graft can be ligated and buried upon decannulation without re sternotomy.²¹

In the presence of isolated RV dysfunction, the selective cannulation of the PA may be considered. Direct PA cannulation or a minimally invasive approach *via* a percutaneous access through the right jugular vein is another option.²² Currently, the PA cannulation may be achieved with a single-lumen or double-lumen cannula.²²

In patients with combined cardiac and pulmonary pathology, upper-body hypoxia (differential oxygenation) can occur if myocardial recovery occurs and lung function remains poor. This may be overcome by transition to VV ECMO if myocardial

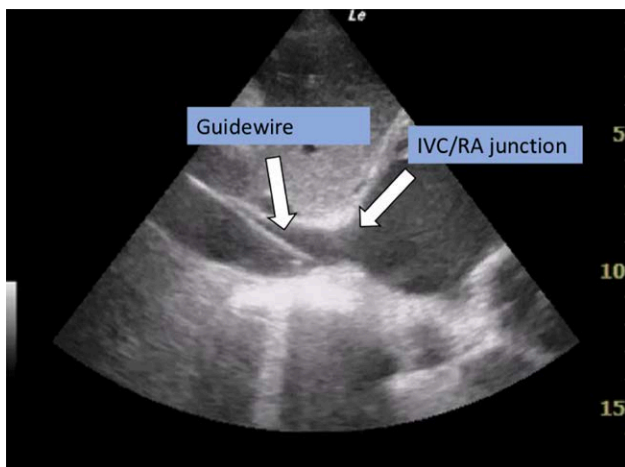


Figure 6. Cardiac echocardiography in the subcostal view demonstrating guidewire position in the IVC/RA junction. IVC, inferior vena cava; RA, right atrium.

recovery is satisfactory or with the use of VAV ECMO, which allows return of oxygenated blood to both arterial and venous sides of the circulation, thereby minimizing the risk of upper-body hypoxia. Returning the oxygenated blood in the ascending aorta by cannulating the axillary or subclavian artery cannulation has also been described in this setting. Moving the femoral drainage cannula up to the orifice of the superior vena cava or higher may let higher oxygen-saturated blood from the inferior vena cava return to the right heart. This may also alleviate upper-body hypoxia to some extent.²³

A more invasive, high-risk option in this setting includes use of the centrifugal ECMO system as a temporary LVAD/biVAD with an oxygenator in the circuit. The device can be employed in several configurations (Table 7) to support both the left or right ventricles and the oxygenator can be removed from the circuit when pulmonary function stabilizes or recovers. This strategy can support patients for a longer period of time, allowing more time to recover, and minimizes the risks of LV distension and thrombosis. This is ideally suited to patients with suspected acute myocarditis in whom myocardial recovery is possible but prolonged support may be required.

Recommendations

- ECMO configuration should be tailored so as to address RV, LV, or biventricular failure.
- Poor pulmonary status with inability to oxygenate leading to differential aortic oxygenation may dictate ECMO configurations requiring:
 - (a) improved cardiac decompression to prevent ejection,
 - (b) VAV cannulation, or
 - (c) in the case of isolated RV failure, use of RA-PA cannulation with a circuit oxygenator (RVAD or OxyRVAD).

Management/Monitoring

The daily care for patients on VA ECMO is complex and requires insights of critical care management and bedside monitoring that arise from the intricate interplay between the extracorporeal circuit and the human body (Table 8 and Figure 10).²⁴⁻²⁶

Cardiovascular Management and Monitoring

Attention to conventional parameters related to appropriate perfusion is the underpinnings of VA ECMO management. Mixed venous saturation provides critical information regarding oxygen supply and demand so difficult to get otherwise. Invasive arterial blood pressure monitoring is imperative in VA ECMO as the pulse pressure reflects the contribution of native cardiac contractility during continuous-flow support. Of importance, when in conjunction with an IABP, assessment of aortic valve opening and the intrinsic LV generated pulse pressure may require changing IABP frequency and echocardiography.²⁶

The right radial artery as well as right upper torso pulse oximetry should routinely be used for blood gas as well as tissue oxygenation to immediately detect upper-body hypoxemia. Reduced capillary pulsatility may hamper adequate pulse ox recordings, which in turn may require more frequent arterial blood gas analyses to guarantee adequate oxygenation.

Method	Factor	Grade of severity		
Arterial line	Arterial Pulsatility	Mild weakness	Moderate weakness	Almost Pulseless
Central venous Line	ScvO ₂	75-55%	55-45%	<45%
	CVP	8-12 mmHg	12-16 mmHg	> 20 mmHg
Echocardiogram	AV	Opening every 2 bpm	Opening every 3-4 bpm	Closure
	LV distension	Mild	Moderate	Severe
	LA distension	Mild	Moderate	Severe
	"Smoke like" effect	Mild	Moderate	Severe
	IVC dilatation ¹	1.5 to 2.5 cm	>2.5 cm	>2.5 cm
	IVC collapse ²	<50%	<50%	No change
Swan Ganz Catheter	PCWP	13-18 mmHg	18-25 mmHg	>25 mmHg
Chest X-ray	Congestion ³	Alveolar edema	Interstitial edema	Redistribution

Less-Invasive
LV-Unloading
Maneuvers
To Be Applied

IABP + Less-Invasive
LV Unloading
Maneuvers
To Be Applied

Invasive
Catheter-Based
LV-Unloading
Maneuvers
To Be Applied

ScvO₂: central venous blood oxygen saturation; CVP: central venous pressure; AV: aortic valve; bpm: beats per minute; LV: left ventricle; LA: left atria; PCWP: post capillary wedge pressure.

Figure 7. Criteria to be used for the assessment of LV unloading need.¹³ AV, aortic valve; bpm, beats per minute; CVP, central venous pressure; IABP, intra-aortic balloon pump; LA, left atria; LV, left ventricular; PCWP, postcapillary wedge pressure; SVCO₂, superior vena cava oxygen saturation.

A pulmonary artery catheter (PAC or Swan-Ganz) should be considered during VA ECMO, as it allows detection of elevated left-sided filling pressures, which may prompt the use of adjunct LV unloading techniques (link to section "LV unloading in VA ECMO").^{2,26} As discussed above, PAC-based continuous cardiac output monitoring during VA ECMO is inaccurate, but it may provide an indication of pulmonary artery flow and aid in weaning. Alternatively, the latter can be monitored by measuring end-tidal CO₂.

The measurement of central venous pressure (CVP) as well as central venous and mixed venous oxygen saturations should be interpreted with caution. All these parameters may critically depend on the cannulation mode and site, and the mutual contribution of the extracorporeal circuit and the native cardiovascular and respiratory system.

A current mainstay of VA ECMO management and monitoring is echocardiography and vascular ultrasound. Its indications

range from early cardiac diagnostics and identification of contraindications to VA ECMO, to visualization of proper vascular access and guidance of the cannulation procedure, optimal tailoring of extracorporeal support and serial assessment of hemodynamic and cardiac condition to ultimately a weaning trial from VA ECMO (link to section "weaning").^{2,26,27} In this context, it is essential to note that the echographer needs to be familiar with the basics of the VA ECMO technique and its impact on cardiovascular pathophysiology. All patients should receive continuous ECG monitoring.²

Respiratory Management and Monitoring

Patients on VA ECMO usually require invasive mechanical ventilation and, although solid data focusing on the VA ECMO population are lacking, a lung protective ventilation strategy including avoidance of barotrauma with a low tidal volume and minute/ventilation, and maintenance of alveolar inflation with relatively high positive end-expiratory pressure (PEEP) are advisable.²⁸ A higher PEEP may also aid to counterbalance elevated hydrostatic pressures, which may arise in the pulmonary vasculature during incomplete LV unloading and cause pulmonary edema.^{16,24} The latter can also be caused or aggravated by reduced pulmonary blood flow or even pulmonary ischemia in high-flow VA ECMO, or a positive daily fluid balance, the latter being associated with worse outcomes in VA ECMO.²⁸

As pulmonary edema is a feared complication in VA ECMO, it should be carefully monitored by repeated chest x-rays film or lung ultrasound, as it may impact on short- and long-term prognosis.^{2,14,28,29} Extubation on ECMO should be considered to reduce the risks of mechanical ventilation and facilitates mobilization, physical rehabilitation, and communication with family and caregivers.^{30,31} All specific aspects of cardiovascular/respiratory management and monitoring during VA ECMO are summarized in Table 9.

Specific Aspects of Critical Care Management

Major complications of VA ECMO are bleeding, thrombosis, and infection. Therefore, protocolized anticoagulation therapy

Table 4. Options, Procedures, and Related Efficacy Potentially Available to Pursue or Favoring Left Ventricular Unloading During Venoarterial Extracorporeal Life Support

Type of Procedure	Efficacy
Less-invasive maneuvers	
Reduced ECMO flow	√√√
Inotropes	√√
Vasodilation	√√
Increased PEEP	√√
Diuretics	√
Invasive (catheter-based) maneuvers	
Trans-aortic suction device	
Impella	√√√√√
Pulsatile trans-aortic suction device	√√√
Atrial septostomy	√√√ - √√√√√
Left ventricular venting through the apex	√√√√√
Left ventricular venting through the mitral valve	√√√√√
Pulmonary artery venting	√√√
IABP	√√
Tran-septal atrial cannula	√√√√
Additional venous cannula	√√
Central ECLS	√√√

ECMO, extracorporeal membrane oxygenation; PEEP, positive end-expiratory pressure; IABP, intra-aortic balloon pump.

Table 5. Advantages and Disadvantages of Central vs. Peripheral Cannulation in Patients Undergoing Postcardiotomy Extracorporeal Membrane Oxygenation¹⁷

	Advantages	Disadvantages
Central cannulation (aortic/atrial)	Use of originally (cardiopulmonary bypass) implanted cannulas Antegrade flow Better drainage (bigger right atrium cannulas) Long-lasting support (subclavian artery use) Higher ECMO flow (better unloading through the right atrium drainage) Patient mobilization (particularly with subclavian artery access) More options (and more easily) for LV venting Lower risk of differential oxygenation	Opened sternum (chest closed possible) High bleeding risk Cardiac compression (if exit port subxiphoid—use different exit sites if possible) Resternotomy to remove cannulas More infection (sepsis) Higher rate of cerebral emboli Higher risk of closed aortic valve
Peripheral cannulation (percutaneous)		
Femoral artery	No surgical incision Reduced bleeding risk Closed sternum No cardiac compression Easier switch to VAD implant	Leg ischemia Retrograde flow (LV afterload increase) Not suitable for long-lasting support Lower ECMO flow Vascular complication (during cannulation or after decannulation) Reduced options for LV venting (percutaneous)
Peripheral cannulation (open)		
Femoral artery	Visualization of peripheral vessel and appropriate cannulation site Reduced bleeding than central access Closed sternum	Lower limb compartment syndrome (in the majority of cases distal perfusion required) Retrograde flow (LV afterload increase) Less suitable for prolonged support—reduced patient mobility Lower ECMO flow (limited right chamber unloading)
Axillary artery	No cardiac compression Avoidance of leg ischemia Avoidance of Harlequin (North/South) Syndrome Patient mobility if prolonged support (bridge to) required Visualization of peripheral vessel and appropriate cannulation site Reduced bleeding than central access Closed sternum No cardiac compression	Upper limb compartment syndrome Upper limb hyperperfusion syndrome (with graft interposition) Higher bleeding risk (site of cannulation) Higher cerebral embolic risk Lower ECMO flow (limited right chamber unloading) Retrograde flow (LV afterload increase, but less than femoral access) Higher rate of vascular complications Time consuming

ECMO, extracorporeal membrane oxygenation; LV, left ventricular; VAD, ventricular assist device.

with close monitoring is a mainstay of VA ECMO management as outlined in detail in a dedicated ELSO guideline and summarized in recent reviews.^{32,33} Close monitoring and aggressive treatment of lower limb ischemia should be established as a protocol, as previously mentioned. The use of cerebral and

lower limb NIRS to assess perfusion is recommended, particularly with peripheral cannulation.

To prevent and treat infectious diseases while on VA ECMO, it should be noted that pharmacokinetics (PK) and pharmacodynamics (PD) of different antibiotics can significantly be

Table 6. ECMO Strategies for Temporary Mechanical Circulatory Support in Isolated Cardiac Failure

ECLS Strategy	Principle Indication(s)
Peripheral VA ECMO (return FA) Central VA ECMO (return aorta)	<ul style="list-style-type: none"> • Default strategy for potentially reversible cardiogenic shock of any cause. • Failure to wean from CPB where recovery expected within 7 d • Salvage for small patients with cardiogenic shock where femoral arterial access inadequate
VA ECMO (return axillary artery)	<ul style="list-style-type: none"> • Reversible cardiogenic shock where high flows not required • Reversible cardiogenic shock with lower limb vascular disease. • Post aortic dissection operation
Centrifugal LVAD (access LA/LV, return aorta) Centrifugal RVAD (access RA, return PA) Centrifugal BiVAD	<ul style="list-style-type: none"> • Isolated LV support where recovery is expected in 8 weeks • Isolated RV support where recovery is expected in 8 weeks • Biventricular support where recovery is expected in 8 weeks

CPB, cardiopulmonary bypass; ECLS, extracorporeal life support; FA, femoral artery; FV, femoral vein; LA, left atrium; LV, left ventricle; LVAD, left ventricular assist device; PA, pulmonary artery; RV right ventricle; RVAD, right ventricular assist device; VA ECMO, venoarterial extracorporeal membrane oxygenation.

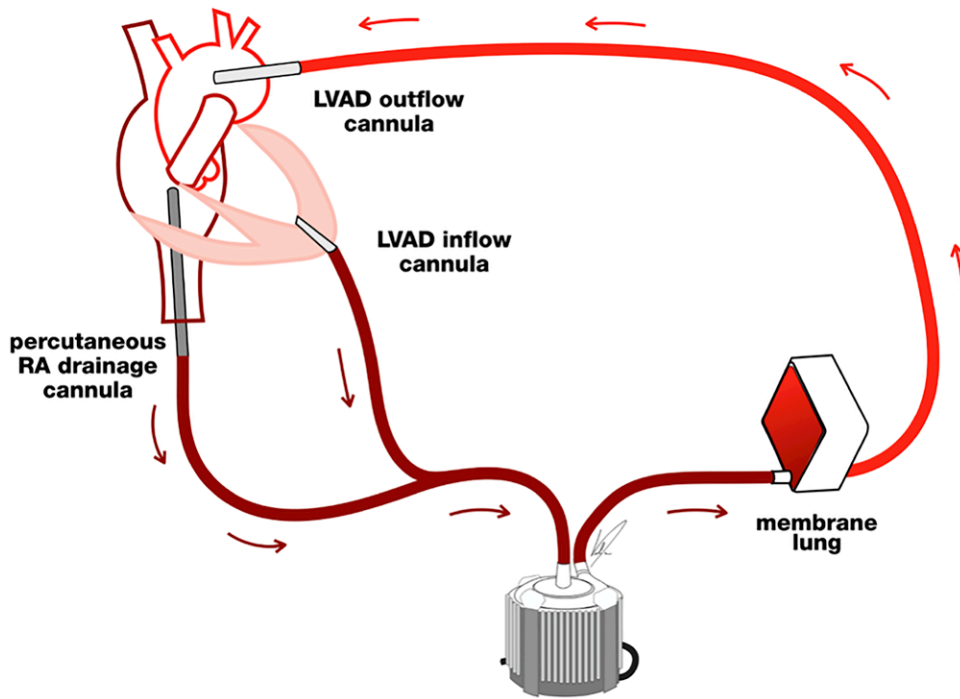


Figure 8. Provision of biventricular assistance along with respiratory support. The extracorporeal membrane oxygenation system can be used as a biventricular assist device along with respiratory support provided by the oxygenator in the circuit (adapted with permission from SAGE Publications).³⁴ LVAD, left ventricular assist device; RA, right atrium.

altered through VA ECMO and critical illness and may require dose adaptations and close drug monitoring.² This holds especially for those patients with concomitant hepatic or renal insufficiency.

Regarding sedation, if hemodynamic, and respiratory conditions allow, awakening, and even extubation could be pursued in the VA ECMO setting. Indeed, patients on ECMO for profound shock may have sustained brain injury before ECMO. All patients should be, therefore, awakened as soon as possible after stable ECMO is established to assess neurologic status. If neurofunction is normal, care proceeds with the intent of cardiac recovery. If there is evidence of major brain damage, care should proceed long enough for repeat neurologic exam (1–2 days). If there is no neurologic improvement, terminating ECMO for futility should be considered.

Upon initiation of VA ECMO, it is evident that patients’ prognosis is largely determined by the severity and reversibility of the underlying disease and concomitant multiorgan system injury. Importantly, the people’s physical condition and neurocognitive function is of utmost importance to prognosticate outcome, whether bridging to recovery, long-term MCS or transplantation.^{24,31}

In summary, critical care management of VA ECMO management includes the well-recognized issues of mechanical ventilation, organ perfusion, infections, neuromonitoring, physical therapy, nutrition, but specifically requires attention to anticoagulation, limb ischemia, differential oxygenation, LV distension, fluid balance, drug distribution and elimination, PK/PD, and CRRT, as summarized in Table 10 and Figure 10.

Recommendations

- Critical care monitoring should emphasize:

- Systemic venous saturation, assuring adequate oxygen delivery
- Assessment of right-sided tissue perfusion including limb and cerebral NIRS to timely diagnose differential oxygenation
- Pulse pressure to assess intrinsic cardiac function
- Lung protective ventilation
- Intermittent monitoring:
 - Lactates, free hemoglobin, D-dimer, blood cell, and related parameters
 - Neurologic examination
- The use of a pulmonary artery catheter (Swan-Ganz) to assess left-sided pressures
- Standardized multimodal neuromonitoring to detect acute brain injury
- Consideration of awakening and extubation, as soon as hemodynamic stability, particularly if support is prolonged

Complications of Venous Arterial ECMO

VA ECMO is an invasive procedure, and complications are common and potentially life threatening. Therefore, early recognition and treatment are very important. Optimal patient management to avoid complications will very likely improve outcomes (Tables 10 and 11).

Complications of Cannulation

Vessel injury with massive hemorrhage, malpositioning and distal ischemia are not uncommon with the use of large cannulas, which are necessary to achieve sufficient flow. Therefore,

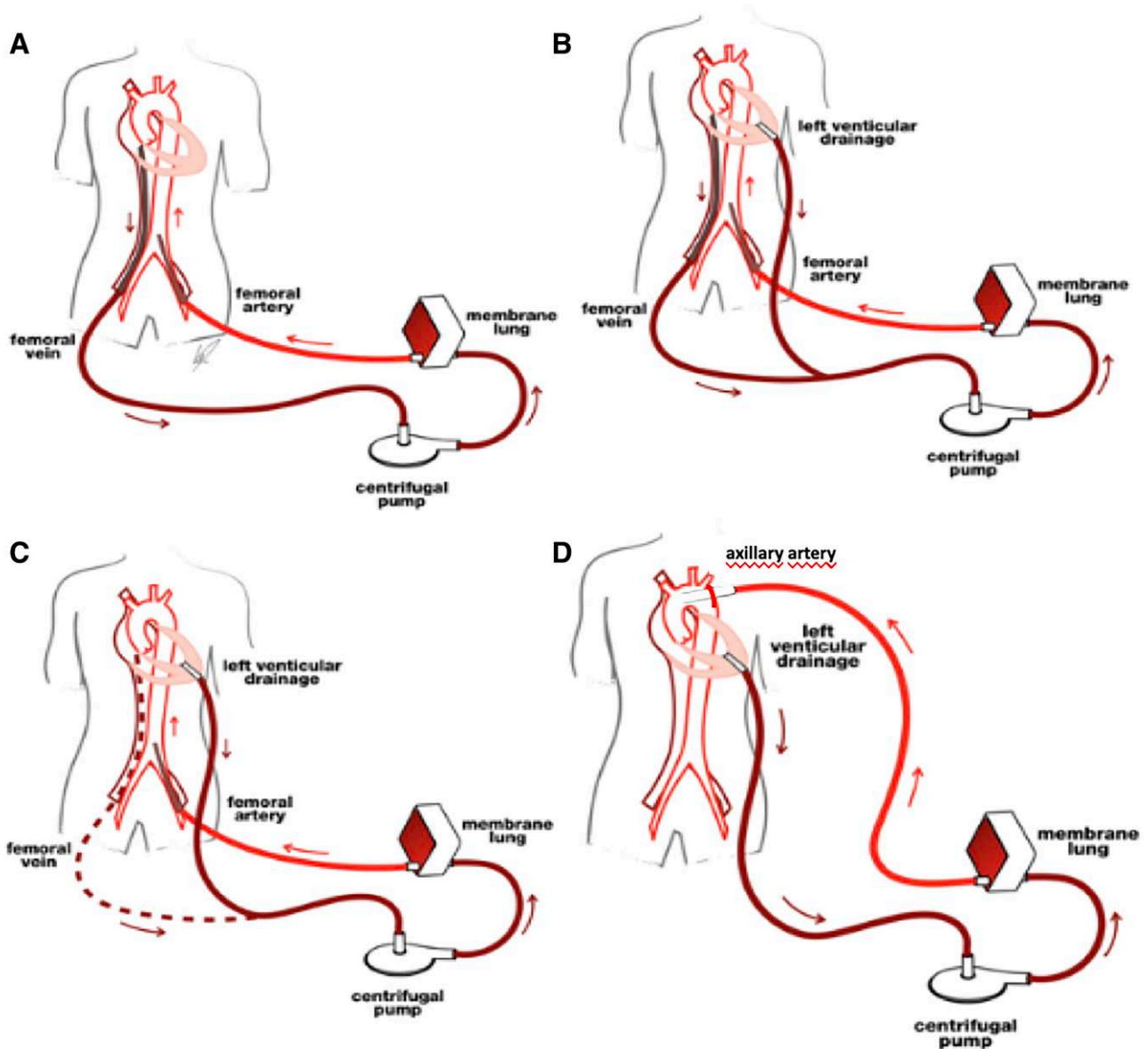


Figure 9. From peripheral venoarterial ECMO to the use of ECMO as a temporary ventricular assist device without sternotomy with the need of concomitant respiratory support. A: Standard femoro-femoral venoarterial ECMO configuration. B: Left ventricular apical cannulation and decompression via thoracotomy approach. C: Removal of right atrial drainage cannula upon right ventricular recovery and provision of isolated temporary left ventricular support. D: Axillary artery cannulation to facilitate early mobilization.²⁰ ECMO, extracorporeal membrane oxygenation.

cannulation should be done only by experienced operators with high-quality equipment (cannula, dilators, and guidewires). While the use of a small distal perfusion cannula will reduce the incidence of leg ischemia from 25.4% to 9.7%,² there may be an increased risk for clot formation in the femoral artery between the return cannula and the distal perfusion cannula, which leads some clinicians to favor surgical decannulation. Percutaneous implantation with Seldinger technique may decrease local infectious complications and possibly bleeding when compared to an open technique.³⁵ However, superiority of percutaneous technique over open cannulation has not conclusively shown and further investigation in this respect are still warranted. Furthermore, as the risk of malpositioning of cannulas is significant, continuous use of imaging techniques

(ultrasound or fluoroscopy) for puncture and positioning is strongly advisable. Thrombo-embolic events are underestimated and may occur in more than 25% of the patients.^{36–38}

Complications Specific to the ECMO Circuit

A common technical problem of all ECMO devices is progressive thrombotic deposition within the circuit, especially in the oxygenator (>10%).¹ This can lead to failure necessitating acute exchange. Clots within the pump head occur in <4% and cause massive hemolysis.³⁹ Significant hemolysis unrelated to ECMO is observed after prolonged resuscitation but should rarely occur in a well-operating modern ECMO device.⁴⁰ ECMO does cause thrombocytopenia, activation

Table 7. Advanced ECLS Strategies for Cardiac and Respiratory Support

ECMO Strategy	Principle Indication(s)
VA ECMO return femoral artery VA ECMO return axillary artery	<ul style="list-style-type: none"> • Default strategy for potentially reversible cardiogenic shock of any cause. • Reversible cardiogenic shock where high flows not required • Reversible cardiogenic shock with lower limb vascular disease. • Reversible cardiogenic shock with poor gas exchange—Expected long-term support with patient mobilization
VA ECMO return ascending aorta	<ul style="list-style-type: none"> • Failure to wean from CPB where recovery expected within 7 d • Salvage for small patients with cardiogenic shock where femoral arterial access inadequate
VAV ECMO	<ul style="list-style-type: none"> • Salvage for severe combined cardiac and respiratory failure • Patients developing circulatory instability on VV ECMO
VPA ECMO	<ul style="list-style-type: none"> • Salvage for severe combined cardiac and respiratory failure • Reversible RV dysfunction expected duration up to 2 wks • Reversible isolated RV dysfunction expected duration up to 8 wks with plan to remove oxygenator and convert to RVAD
Centrifugal RVAD femoral access + oxygenator Centrifugal RVAD-RA access + oxygenator	<ul style="list-style-type: none"> • Severe LV afterload mismatch on VA ECMO. • Severe combined cardiac and respiratory failure where early RV recovery is expected before intermediate-term LV recovery
Centrifugal hybrid (requires oxygenator)	

Bridging to intermediate or long-term support may be required.

CPB, cardiopulmonary bypass; ECLS, extracorporeal life support; FA, femoral artery; FV, femoral vein; LA, left atrium; LV, left ventricle; LVAD, left ventricular assist device; PA, pulmonary artery; RA: right atrium; RV, right ventricle; RVAD, right ventricular assist device; VA ECMO, venoarterial extracorporeal membrane oxygenation; VAV, venoarterial/venous; VPA, veno-pulmonary; VV, veno-veno.

of platelets, decrease of coagulation factors, for example, of large von-Willebrand-Factor multimers and fibrinogen which together with therapeutic anticoagulation, increases the risk of hemorrhage substantially. Neurologic complications are frequent in VA ECMO (15.1% in a registry cohort).⁴¹ Activation of the inflammatory cascade, heparin-induced thrombocytopenia or infection of circuits occur but rarely cause a major clinical problem.²

Complications Specific to VA ECMO

It is thought that VA ECMO increases LV afterload; however, the negative effect is the actual rise in blood pressure due to the retrograde flow in relation to a poorly contractile LV generating reduced stroke volume and, hence reduced aortic valve opening or protracted closure, sometimes. Therefore, VA ECMO flow should be established at the lowest flow, which provides adequate organ perfusion and avoids anaerobic metabolisms while enhancing forward LV flow. LV distension may, however, develop with increased wall tension, myocardial ischemia, delayed recovery, pulmonary edema, and clot formation in the left cardiac chambers at any ECMO flows, depending on the residual LV contractility.^{2,14} “Differential oxygenation” describes a situation when the lower body is perfused by ECMO-oxygenated blood, but variable parts of the upper body (coronaries, right arm, brain) receive hypoxemic blood when the LV recovers and there is simultaneous severe lung failure.² Because hypoxic damage to the heart and brain can happen, to recognize timely blood gas analysis and saturation must be taken from the right arm. If optimization of ventilation does not resolve the problem, an additional return cannula to the jugular vein (VAV ECMO) may become necessary. Finally, significant hyperoxemia and hypocapnia can easily occur postmembrane, which will perfuse the organs of the (lower) organism undiluted. Both hyperoxemia and hypocapnia with respiratory acidosis are known to have detrimental effects on outcome and have to be avoided by measurement

of postmembrane arterial blood gases after every change of ECMO settings, including adjustment of oxygen-blending and total gas flow.

Recommendations

- Ultrasound guidance is recommended for percutaneous cannulation.
- In the presence of large-sized cannulas, surgical decannulation is recommended.

Table 8. Clinical Monitoring During Venoarterial Extracorporeal Membrane Oxygenation

Invasive arterial blood pressure monitoring/right radial artery
<ul style="list-style-type: none"> • Pulse pressure—measure of native contractility vs. ECMO blood flow • Oxygen saturation—measure of oxygenation in proximal aortic arch/detection of differential oxygenation
Pulse oximetry/right hand
<ul style="list-style-type: none"> • Oxygen saturation—measure of oxygenation in proximal aortic arch/detection of differential oxygenation
Pulmonary artery catheter
<ul style="list-style-type: none"> • Detect elevated left-sided filling pressure • Support indication for adjunct LV unloading • Continuous cardiac output monitoring as indication of residual pulmonary artery flow (alternatively, residual pulmonary artery flow can be monitored by measuring end-tidal CO₂)
Echocardiography
<ul style="list-style-type: none"> • Early cardiac diagnostics and identification of contraindications to VA ECMO • Visualization of proper vascular access and guidance cannulation • Optimal tailoring of ECMO support • Serial assessment of hemodynamic and cardiac conditions • Cardiac assessment during weaning trial
Electrocardiography
<ul style="list-style-type: none"> • Consider continuous, multilead electrocardiographic monitoring
NIRS
<ul style="list-style-type: none"> • Monitoring of limb (single and bilateral comparison) and brain perfusion

ECLS, extracorporeal life support; LV, left ventricular; NIRS, near-infrared spectroscopy; VA ECMO, venoarterial extracorporeal membrane oxygenation.

	Monitor for	Treatment
Rhythm	Dysrhythmias such as ventricular fibrillation that may prevent ventricular ejection	Antiarrhythmics Cardioversion Pacing Ablation
MAP	Hypotension (MAP=COxSVR) (i) Inadequate VA-ECMO flow (ii) Inadequate DVR	(i) See "Flow" below (ii) Start vasoconstrictor
Pulsatility	Lack of pulsatility on arterial waveform caused by (i) poor myocardial function (ii) excessive VA-ECMO support (iii) inadequate preload (iv) RV failure May result in (i) thrombus (ii) myocardial ischemia (iii) pulmonary edema (assess CXR, wedge(If poor myocardial function, consider: decreasing VA-ECMO flow starting or increasing inotrope starting or increasing vasodilator IABP Myocardial decompression
Flow (L/Min)	Low flows (assuming centrifugal pump) (i) Inadequate preload (a) hypovolemia (may see hemolysis, chattering) (b) mechanical obstructive (ii) Excessive afterload (thrombus, kink, SVR) (iii) Inadequate RPM	(i) Volume: crystalloid/colloid/transfusion Release of mechanical obstruction (ii) Exchange oxygenator, relieve cannula kink, vasodilator to decrease SVR (iii) Increase RPM
Gas Exchange	Inadequate PaO ₂ inadequate or excessive CO ₂ elimination (i) VA-ECMO settings (a) FiO ₂ (b) VA-ECMO flow (c) Sweep gas flow rate (ii) Oxygenator function (a) Pre and postmembrane pressures (b) Pre and postoxygenator gases (iii) Upper body hypoxemia (femoral-femoral cannulation	(i) If hypoxemia, increase FiO ₂ or flow. If hypercarbia, increase sweep. If hypocarbia, decrease or add CO ₂ (ii) Increased AP and inadequate arterialization of postoxygenerator gases suggest oxygenator malfunction (iii) Increase pulmonary venous O ₂ content Adjust ventilator settings. Treat etiology of pulmonary dysfunction. Increase VA-ECMO flow. Change to axillary/carotid cannulation. VA-V-ECMO. VV-ECMO
Oxygen Delivery: SvO ₂ and Lactate	Decreased SvO ₂ and increasing lactage suggest inadequate oxygen delivery (DO ₂ =COxCaO ₂) (i) VA-ECMO flow (ii) Hemoglobin (iii) SaO ₂ Excessive oxygen consumption (ER=VO ₂ /DO _s) (i) Febrile (ii) Shivering	(i) Increase VA-ECMO flow (ii) Transfuse (iii) Ensure adequate gas exchange (i) Antipyretics (ii) Consider agents such as meperidine or dexmedetomidine
Distal limb Ischemia	Loss of pulses Cyanosis and coolness of limb	Femoral-femoral cannulation DP or PT antegrade perfusion catheter
Anticoagulation	Adequate heparinization by PTT	
Temperature	Normothermia unless therapeutic hypothermia	

Figure 10. Approach to monitoring and managing the VA ECLS patient. (Permission to use granted under Creative Commons Attribution License) (from ELSO Red Book 5th Edition, 2017).² VA ECLS, venoarterial extracorporeal life support.

Table 9. Clinical Management During Venoarterial Extracorporeal Membrane Oxygenation

Mechanical ventilation
<ul style="list-style-type: none"> • Apply lung protective ventilation strategy with Vt 6–8 ml/kg ideal body weight. • Avoid pulmonary edema (LV distension monitoring and prevention, pulse pressure >10 mmHg and aortic valve opening assessment, higher PEEP, vasodilators, ECMO flow adjustment, moderate inotropes, diuretics, or venting strategies as indicated and according to local expertise and resources) • Promote mobilization • Consider extubation
General critical care management
<ul style="list-style-type: none"> • Protocolize anticoagulation therapy and monitoring • Consider multimodal neuromonitoring/neuroimaging • Close monitoring and aggressive treatment of lower limb ischemia, including embolectomy, vessel repair, revascularization, and fasciotomy • Consider altered pharmacokinetics/drug dosing • Strive for a neutral/negative fluid balance • Connect CRRT device to ECMO circuit, if required

CRRT, continuous renal replacement therapy; ECMO, extracorporeal membrane oxygenation; LV, left ventricular; PEEP, positive end-expiratory pressure.

- Cannula malposition should be ruled out in cases of problematic ECMO flow and oxygenation.
- Clot formation, either at the arterial or venous cannulation sites, may occur during and after ECMO support.
- The addition of a supplementary return cannula (more often to the superior vena cava) should be considered in the presence of differential oxygenation and refractory respiratory insufficiency (VAV ECMO).
- Excessive hypo- and hyperoxemia should be avoided.

- Rapid hypocapnia at ECMO start should be also avoided to reduce cerebral vasoconstriction and subsequent complications.

Weaning From VA ECMO

VA ECMO weaning should be considered when patients have experienced sufficient cardiac recovery, specifically, the need for minimal vasoactive, inotropic support to maintain an adequate pulse pressure >10 mmHg (PP), mean arterial pressure (MAP) of >65 mmHg, and mixed venous/central sat at 2–2.5 L/min of VA ECMO flow.²

Adequate anticoagulation should be assured during phases of low pump flow and weaning trials. Echocardiography during weaning trials is critical and recommended to assess biventricular function, presence of valvular dysfunction as well as LVOT VTI, which is a surrogate of cardiac output. Swan-Ganz catheter might be useful in this phase to objectively evaluate left-sided pressures and cardiac output with the VA ECMO circuit clamped. During weaning, VA ECMO flow is decreased progressively by 500ml every 5–10 minutes. Patients are evaluated after 3–5 minutes of no support (circuit clamped) or alternatively at minimum of 1 L/min of support. Even minimal ECMO flow leads to reduced preload of the right ventricle, and therefore right heart function may not be fully tested when clamping of the ECMO circuit or “zero flow” is used. Pump Controlled Retrograde Trial Off is a weaning technique that can be considered. The arterial flow probe is reversed, and 1 L of flow is returned to the right atrium and right ventricle via venous cannula.⁴² In addition, with the sweep turned off, this technique allows for accurate assessment of lung function. Successful weaning is expected if the following parameters are

Table 10. Major Complications of Venoarterial Extracorporeal Membrane Oxygenation and Suggested Management

Complication	Management
Malpositioning of cannula	Routine use of ultrasound/fluoroscopy for cannulation procedure
Ischemia of cannulated leg	Prophylactic use of small antegrade perfusion cannula, NIRS monitoring of calf muscle before, during and after VA ECMO oximetry, pulse Doppler of cannulated leg
Deep vein thrombosis of femoral/caval vein	Adequate anticoagulation during and after VA ECMO, Ultrasound control of vessels after decannulation
Overloading of LV	Reduce MAP to lowest acceptable value Use a small dose of inotropes, avoid vasopressors if possible Use PAC and end-tidal CO ₂ for monitoring of pulmonary perfusion Regular echocardiography
Differential oxygenation	Venting of LV when indicated (see proper table) Monitoring of BGA and saturation on right arm NIRS monitoring of the brain and lower limbs Optimize ventilation
Lower body hyperoxemia/hypocapnia	VAV cannulation only if necessary BGA post membrane after every change in ECMO settings Adjust gas flow and blender settings to achieve Normocapnia and slight hyperoxemia (150 mmHg) after the oxygenator
Device clotting	Adequate anticoagulation Regular maintenance by control of aPTT or ACT, D-Dimers, trans-membrane pressure and gas transfer capacity—If relevant, timely system replacement
Hemorrhage	Adequate anticoagulation (reduced or stop heparin administration in case of excessive bleeding or life-threatening hemorrhage) Regular control of aPTT or ACT, platelets, fibrinogen NIRS monitoring of brain Avoid every unnecessary invasive procedure

ACT, activated clotting time; aPTT, activated prothrombin time; BGA, blood gas analysis; CO₂, carbon dioxide; LV, left ventricle; MAP, mean arterial pressure; MAP, mean arterial pressure; NIRS, near-infrared spectroscopy; PAC, pulmonary artery catheter; VA ECMO, venoarterial extracorporeal membrane oxygenation; VAV, venoarterial/venous.

Table 11. Incidence of Selected Complications of Venoarterial Extracorporeal Membrane Oxygenation, ELSO Registry, 2014–2018 (reported runs: 14,580, survival overall: 44%)¹

Complication	Reported Incidence (%)	Survival to Discharge (%)
Circuit component clots	9.2	41
Hemolysis (fHb > 50 mg/dl)	3.4	32
Cannulation site bleeding	12.5	38
Surgical site bleeding	14.5	33
Cardiac tamponade	4.4	37
Pulmonary hemorrhage	2.3	23
CNS hemorrhage (US or CT)	1.4	11
CNS infarction (US or CT or MRI)	3.5	22
Renal replacement therapy required	29.6	31
Culture proven infection	7.6	40
Limb ischemia	5.3	30
Limb amputation	0.7	52

CNS, central nervous system; CT, computer tomography; fHb, plasma-free hemoglobin; MRI, magnetic resonance imaging; US, ultrasound.

met: MAP > 60 mmHg, LVOT VTI > 0.12 m/s, tissue Doppler lateral mitral annulus peak systolic velocity ≥ 6 cm/sec, CVP ≤ 10 mmHg, and LV ejection fraction ≥ 25%–30% on low doses of 1–2 inotropes or pressors.^{2,27}

Low dose inotropes and pressors are defined as follow:

- dopamine < 3 µg/kg/min,
- dobutamine < 3 µg/kg/min,
- milrinone < 0.3 µg/kg/min,
- norepinephrine < 0.06 µg/kg/min,
- epinephrine < 0.1 µg/kg/min,

- phenylephrine < 1 µg/kg/min,
- vasopressin < 0.03 µg/kg/min.

After a successful weaning trial, decannulation should promptly occur to avoid potential complications that are associated with ECMO support.

Patients who are unable to wean from VA ECMO support within 5–7 days could be considered for temporary LVAD support to allow more time for LV recovery as long as RV systolic function is preserved (Figure 11). Patients with known severely reduced LV systolic function before VA ECMO placement could be considered for earlier LVAD implantation or heart transplantation. Candidacy for advanced therapies should be based on the current International Society for Heart and Lung Transplantation guidelines but is often center specific. Most centers consider lack of neurologic recovery, multiorgan failure, advanced age, inadequate social support, or metastatic cancer as contraindications to durable LVAD support and heart transplantation and early referral to these centers is recommended if appropriate. When faced with futility of care in patients who are not candidates for advanced therapies, it is reasonable to proceed with a palliative approach and withdrawal of care. Early involvement of palliative care services should be considered in all patients supported with VA ECMO to assist with management of expectations, the goals of care, and family support.

Recommendations

- VA ECMO weaning should be considered when patients exhibit stable hemodynamics in the face of reduced ECLS flow, including MAP > 60 mmHg, LVOT VTI > 0.12 m/s, tissue Doppler lateral mitral annulus peak systolic

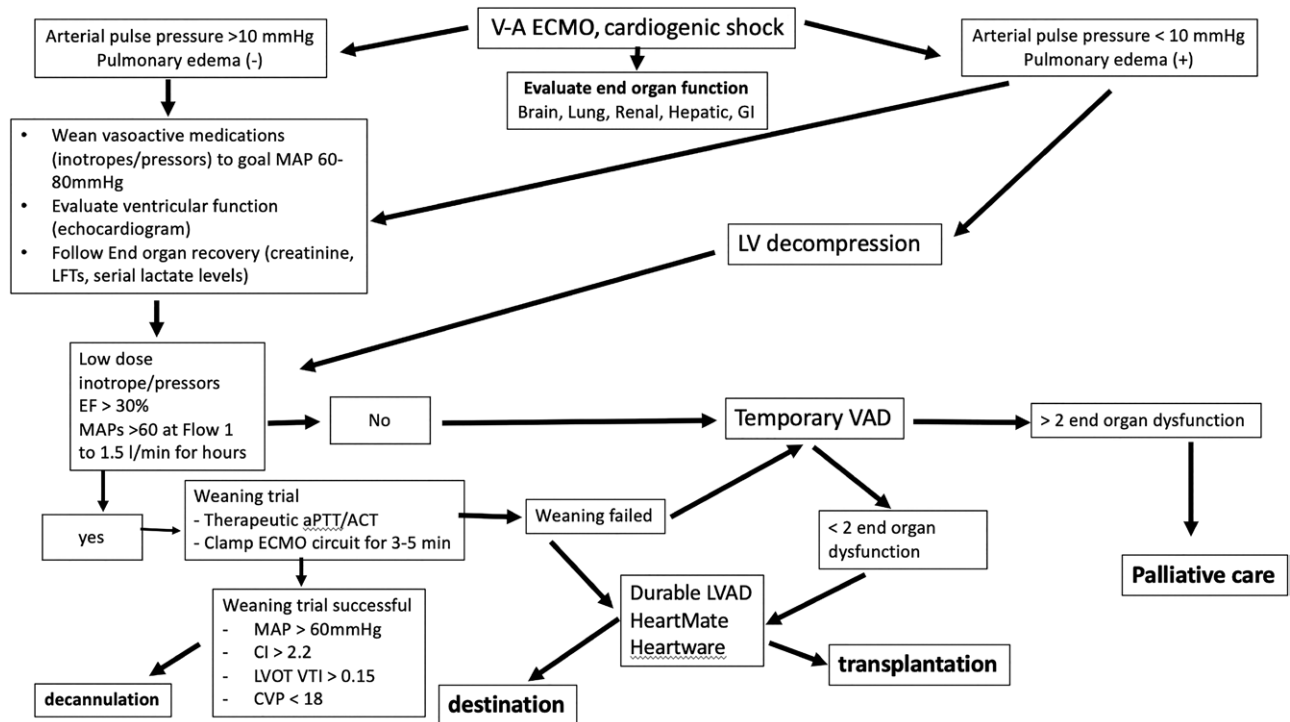


Figure 11. Algorithm for ECMO team approach and decision making for venoarterial extracorporeal membrane oxygenation implant and related management in patients with cardiogenic shock. ACT, activated coagulation time; CI, cardiac index; CVP, central venous pressure; GI, gastrointestinal; LFT, liver function test; LVAD, left ventricular assist device; LVOT VTI, left ventricular outflow tract velocity time integral; MAP, mean arterial blood pressure; PTT, partial thromboplastin time; VA ECLS, venoarterial extracorporeal life support.

velocity ≥ 6 cm/sec, CVP ≤ 10 mmHg, and LV ejection fraction $\geq 25\%$ – 30% on low doses vasoactive, inotropic support.

- Pump Controlled Retrograde Trial Off or a shunt installed between the arterial and venous circuit arms allow hemodynamic assessment with reduced or negligible ELSO circuit support

Ethics

ECMO provides a form of therapy that poses ethical dilemmas by virtue of its ability to temporarily suspend native cardiopulmonary function as a requirement for life.² The ECMO team must resist the temptation to act first and think later, but rather govern the use of ECMO in a way that not only honors life but also death (Figure 11). Addressing the ethical dilemmas surrounding its use relate to (a) the patient and his or her family, (b) the caregiving team, and (c) society.

The Patient and the Family

The issue of consent is generally moot because the situations in which ECMO is used are usually emergent such that the opportunity for comprehensive consent rarely exists. Consequently, family education must begin soon after its institution. The patients' next-of-kin must be made aware of this and discussions regarding possible discontinuation of ECMO support and provision of appropriate palliative care should begin early, particularly in situations where ECMO is unlikely to be successful.^{43,44} Early institution of palliative or supportive care teams, psychologic counselors, or even ethics teams, may be of considerable help in framing these difficult issues and providing personal support to help family members who are usually unprepared for such challenging shared decision making.²

The ECMO Team

Dissension within the ECMO team can result as a consequence of differences in opinion about the utilization of ECMO for high-risk patients. An agreed-upon list of inclusion and exclusion criteria, determined by a multidisciplinary committee, can avoid some of this.² Open discourse within the team regarding goals of care, the approach to families, and duration of ECMO should be fostered.

The Society

In most societies, ECLS is not a therapy known to or discussed among the lay public, with the notable exception of Taiwan.⁴⁵ Although the capability of ECMO to support patients is remarkable, in many clinical situations, the evidence to support its use is relatively low. Added to this is the issue of its cost, both in financial terms, resource utilization, and the effect on families frequently unprepared to deal with the issues of futility of care. Nonetheless, ECMO has been demonstrated to be life-saving and cost-effective in several clinical scenarios.²

Recommendations

- Before the institution of ECMO, decision making should include the chances of myocardial recovery, and, if not, the possibility of bridging to durable MCS or transplantation.

- Immediate education of the family should involve a discussion of the prognosis, the possibility of bridging to advanced therapies, and what would be a reasonable duration of support should recovery not occur, in conjunction with the patient's family.
- An ECMO Team fluent in the care of these patients should be established in centers planning on providing this therapy.
- Creation of a regional hub-&-spoke network with more experienced centers should be established for hospitals unable to provide ECMO.
- Training and retraining must be part of the ECMO program.

Acknowledgments

We thank Elaine Cooley, MSN, RN, Peter Rycus, MPH, and the ELSO Board Members for help in the overall process.

References

1. Extracorporeal Life Support Organization: The ELSO International Report 2019. Available at: <https://www.else.org/Registry/Statistics/InternationalSummary.aspx>.
2. Brogan T, Lequier L, Lorusso R, MacLaren G, Peek G: *The ELSO Red Book*, 5th ed. ELSO eds, Ann Arbor, MI, ELSO, 2017.
3. Conrad SA, Broman LM, Taccone FS, et al: The ELSO Maastricht treaty for nomenclature for extracorporeal life support. *Am J Respiratory Crit Care Med* 198, 447–451, 2018.
4. Broman LM, Taccone FS, Lorusso R, et al: The ELSO Maastricht Treaty for ECLS Nomenclature: Abbreviations for cannulation configuration in extracorporeal life support - a position paper of the Extracorporeal Life Support Organization. *Crit Care* 23: 36, 2019.
5. Lorusso R, Whitman G, Milojevic M, et al: 2020 EACTS/ELSO/STS/AATS expert consensus on postcardiotomy extracorporeal life support. *ASAIO J* 67, e1–e43, 2021.
6. McMurray JJ, Adamopoulos S, Anker SD, et al; ESC Committee for Practice Guidelines: ESC Guidelines for the diagnosis and treatment of acute and chronic heart failure 2012: The Task Force for the Diagnosis and Treatment of Acute and Chronic Heart Failure 2012 of the European Society of Cardiology. Developed in collaboration with the Heart Failure Association (HFA) of the ESC. *Eur Heart J* 33: 1787–1847, 2012.
7. Schmidt M, Burrell A, Roberts L, et al: Predicting survival after ECMO for refractory cardiogenic shock: The survival after venoarterial-ECMO (SAVE) score. *Eur Heart J* 36: 2246–56, 2015.
8. Muller G, Flecher E, Lebreton G, et al: The ENCOURAGE mortality risk score and analysis of long-term outcomes after VA-ECMO for acute myocardial infarction with cardiogenic shock. *Intensive Care Med* 42: 370–378, 2016.
9. Wang L, Yang F, Wang X, et al: Predicting mortality in patients undergoing VA-ECMO after coronary artery bypass grafting: The REMEMBER score. *Crit Care* 23: 11, 2019.
10. Sanchez-Salado JC, Lorente V, Alegre O, Liao I, Blazquez L, Ariza-Sole A: Predictive ability of the CardShock score in patients with profound cardiogenic shock undergoing venoarterial extracorporeal membrane oxygenation support. *Med Intensiva* 44: 312–315, 2019.
11. Brogan T, et al (eds). *ELSO Specialist Manual*, 4th ed. Ann Arbor, MI, Extracorporeal Life Support Organization (ELSO), 2018.
12. Rupperecht H, Lunz D, Philipp A, Lubnow M, Schmid C: Pitfalls in percutaneous ECMO cannulation. *Heart Lung Vessel* 7: 320–326, 2015.
13. Di Gennaro JL, Chan T, Farris RWD, Weiss NS, McMullan DM: Increased stroke risk in children and young adults on extracorporeal life support with carotid cannulation. *ASAIO J* 65: 718–724, 2019.
14. Meani P, Denoij T, Raffa GM, et al: Protracted aortic valve closure during peripheral veno-arterial life support: Is the intra-aortic balloon pump the solution? *Perfusion* 34: 35–41, 2019.

15. Russo JJ, Aleksova N, Pitcher I, et al: Left ventricular unloading during extracorporeal membrane oxygenation in patients with cardiogenic shock. *J Am Coll Cardiol* 73: 654–662, 2019.
16. Al-Fares AA, Randhawa VK, Englesakis M, et al: Optimal strategy and timing of left ventricular venting during veno-arterial extracorporeal life support for adults in cardiogenic shock: A systematic review and meta-analysis. *Circ Heart Fail* 12: e006486, 2019.
17. Lorusso R, Bidar E, Natour E, Heuts S: Minimally invasive management of central ECMO after ascending aortic surgery. *J Card Surg* 34: 131–133, 2019.
18. Raffa GM, Kowalewski M, Brodie D, et al: Meta-analysis of peripheral or central extracorporeal membrane oxygenation in post-cardiotomy and non-postcardiotomy shock. *Ann Thorac Surg* 107: 311–321, 2019.
19. Mariscalco G, Salsano A, Fiore A, et al; PC-ECMO group: Peripheral versus central extracorporeal membrane oxygenation for postcardiotomy shock: Multicenter registry, systematic review, and meta-analysis. *J Thorac Cardiovasc Surg* 160: 1207–1216.e44, 2020.
20. Massetti M, Gaudino M, Crea F: How to transform peripheral extracorporeal membrane oxygenation in the simplest mid-term paracorporeal ventricular assist device. *Int J Cardiol* 166: 551–553, 2013.
21. Shehab S, Rao S, Macdonald P, et al: Outcomes of venopulmonary arterial extracorporeal life support as temporary right ventricular support after left ventricular assist implantation. *J Thorac Cardiovasc Surg* 156: 2143–2152, 2018.
22. Lorusso R, Raffa GM, Heuts S, et al: Pulmonary artery cannulation to enhance extracorporeal membrane oxygenation management in acute cardiac failure. *Interact Cardiovasc Thorac Surg* 30: 215–222, 2020.
23. Hou X, Yang X, Du Z, et al: Superior vena cava drainage improves upper body oxygenation during veno-arterial extracorporeal membrane oxygenation in sheep. *Crit Care* 19: 68, 2015.
24. Abrams D, Brodie D: The clinical management of patients on partial/total extracorporeal support. *Curr Opin Crit Care* 22: 73–79, 2016.
25. Donker DW, Brodie D, Henriques JPS, Broomé M: Left ventricular unloading during veno-arterial ECMO: A simulation study. *ASAIO J* 65: 11–20, 2019.
26. Donker DW, Meuwese CL, Braithwaite SA, et al: Echocardiography in extracorporeal life support: A key player in procedural guidance, tailoring and monitoring. *Perfusion* 33(suppl 1): 31–41, 2018.
27. Aissaoui N, Luyt CE, Leprince P, et al: Predictors of successful extracorporeal membrane oxygenation (ECMO) weaning after assistance for refractory cardiogenic shock. *Intensive Care Med* 37: 1738–1745, 2011.
28. Schmidt M, Pellegrino V, Combes A, Scheinkestel C, Cooper DJ, Hodgson C: Mechanical ventilation during extracorporeal membrane oxygenation. *Crit Care* 18: 203, 2014.
29. Boulate D, Luyt CE, Pozzi M, et al: Acute lung injury after mechanical circulatory support implantation in patients on extracorporeal life support: An unrecognized problem. *Eur J Cardiothorac Surg* 44: 544–9; discussion 549, 2013.
30. Mirabel M, Luyt CE, Leprince P, et al: Outcomes, long-term quality of life, and psychological assessment of fulminant myocarditis patients rescued by mechanical circulatory support. *Crit Care Med* 39: 1029–1035, 2011.
31. Abrams D, Garan AR, Brodie D: Awake and fully mobile patients on cardiac extracorporeal life support. *Ann Cardiothorac Surg* 8: 44–53, 2019.
32. Extracorporeal Life Support Organization: ELSO Anticoagulation Guidelines 2014. Available at <https://www.else.org/Portals/0/Files/elseanticoagulationguideline8-2014-table-contents.pdf>.
33. Ranucci M: The conundrum of anticoagulation and hemostatic management in ECMO patients. *Minerva Anestesiol* 82: 147–148, 2016.
34. Aggarwal A, Modi S, Kumar S, et al: Use of a single-circuit CentriMag® for biventricular support in postpartum cardiomyopathy. *Perfusion* 28: 156–159, 2013.
35. Dhanial P, Hajage D, Nguyen LS, et al: Percutaneous versus surgical femoro-femoral veno-arterial ECMO: A propensity score matched study. *Intensive Care Med* 44: 2153–2161, 2018.
36. Rastan AJ, Lachmann N, Walther T, et al: Autopsy findings in patients on postcardiotomy extracorporeal membrane oxygenation (ECMO). *Int J Artif Organs* 29: 1121–1131, 2006.
37. Combes A, Leprince P, Luyt CE, et al: Outcomes and long-term quality-of-life of patients supported by extracorporeal membrane oxygenation for refractory cardiogenic shock. *Crit Care Med* 36: 1404–1411, 2008.
38. Fisser C, Reichenbacher C, Müller T, et al: Incidence and risk factors for cannula-related venous thrombosis after venovenous extracorporeal membrane oxygenation in adult patients with acute respiratory failure. *Crit Care Med* 47: e332–e339, 2019.
39. Lubnow M, Philipp A, Foltan M, et al: Technical complications during veno-venous extracorporeal membrane oxygenation and their relevance predicting a system-exchange—retrospective analysis of 265 cases. *PLoS One* 9: e112316, 2014.
40. Lehle K, Lubnow M, Philipp A, et al: Prevalence of hemolysis and metabolic acidosis in patients with circulatory failure supported with extracorporeal life support: A marker for survival? *Eur J Heart Fail* 19(suppl 2): 110–116, 2017.
41. Lorusso R, Barili F, Mauro MD, et al: In-hospital neurologic complications in adult patients undergoing venoarterial extracorporeal membrane oxygenation: Results from the extracorporeal life support organization registry. *Crit Care Med* 44: e964–e972, 2016.
42. Ling L, Chan KM: Weaning adult patients with cardiogenic shock on veno-arterial extracorporeal membrane oxygenation by pump-controlled retrograde trial off. *Perfusion* 33: 339–345, 2018.
43. MacLaren G: When to initiate ECMO with low likelihood of success. *Crit Care* 32: 20, 2018.
44. Ramanathan K, Cove ME, Caleb MG, Teoh KL, MacLaren G: Ethical dilemmas of adult ECMO: Emerging conceptual challenges. *J Cardiothorac Vasc Anesth* 29: 229–233, 2015.
45. Chen YY, Chen L, Kao YH, Chu TS, Huang TS, Ko WJ: The over-optimistic portrayal of life-supporting treatments in newspapers and on the Internet: A cross-sectional study using extracorporeal membrane oxygenation as an example. *BMC Med Ethics* 15: 59, 2014.